



# Autologous Adipose-Derived Biocellular (Stem Cell-Rich) Prolotherapy into Hoffa's Fat Pad Improves Knee Osteoarthritis

*A case series demonstrates improvement in quality and density of the fat pad, knee pain reduction, and increased function in patients with moderate-to-severe knee OA.*

*By Donna D. Alderman, DO, Mira C. Mehra, Tobin C. Paez and Trenton J. Sincomb*

## Osteoarthritis of the Knee: Prevalence and Treatment Gaps

Knee osteoarthritis is a common problem in the US population, with 14 million Americans suffering from symptomatic disease.<sup>1</sup> Development of knee osteoarthritis (OA) can be related to several risk factors, including a sedentary lifestyle, previous knee injury, female gender, obesity, and diabetes.<sup>2</sup>

Individuals are also living longer. In 2017, the CDC reported an average US life expectancy of 78.6 years,<sup>3,4</sup> while in 1970 it was only 56.4 years.<sup>5</sup> This explains the increased prevalence of knee OA in the aging Baby Boomer population.<sup>6</sup>

Traditional treatment options include [NSAIDs](#), corticosteroids, hyaluronic acid, arthroscopic surgery, and, ultimately, joint replacement. NSAIDs and corticosteroids, while sometimes providing relief, are only temporary and may have

detrimental effects;<sup>7-11</sup> [hyaluronic acid](#) has a low success rate (approximately 50%), and is temporary;<sup>12,13</sup> knee arthroscopic surgery is not generally recommended in older adults because studies have shown no appreciable difference in outcome versus placebo;<sup>14,15</sup> and joint [replacement](#) is not without risk.

In 2016, the American Academy of Orthopaedic Surgeons reported a higher number of patients than expected had pain 1 year after total knee replacement (TKA), and recommended that TKA only be considered after all non-surgical treatments have failed.<sup>16</sup> Platelet-rich plasma (PRP) knee injections have been studied in recent years, and while often superior to either corticosteroids or hyaluronic acid,<sup>17-19</sup> PRP tends to be more effective for the early stages of OA.<sup>20,21</sup> Thus, better treatment options are needed, especially for more advanced forms of the disease.

## Newer Treatment Approaches for Painful Knee Osteoarthritis

Mesenchymal stem cells ([MSCs](#)) are an effective treatment option for knee osteoarthritis, with the potential to regenerate cartilage and connective tissue, as well as stimulate the microenvironment toward healing.<sup>22-27</sup> Adipose (fat) is an abundant source of MSCs in the human body.<sup>28-30</sup> Of note in the knee is the infrapatellar fat pad (IPFP), also known as Hoffa's fat pad. Biopsies of healthy IPFPs show high quantities of MSCs.<sup>31</sup> Interestingly, there is a strong correlation between patients with osteoarthritis, dysfunction and pain, and the presence of a depleted, inflamed, and unhealthy fat pad.<sup>32-36</sup>

Adipose-derived biocellular (stem cell rich) prolotherapy uses autologous lipoaspirate (tissue-stromal vascular fraction, t-SVF) extracted from healthy adipose (usually flank/abdomen) in an individual, plus autologous high-density PRP, to create a stem cell-rich formula (t-SVF/PRP), which is then injected back into that same individual, in areas where needed.<sup>37-39</sup>

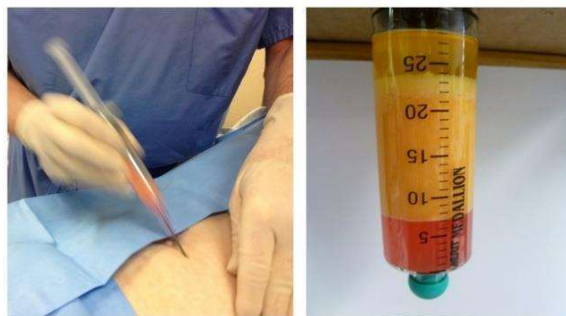
We hypothesized that t-SVF/PRP, injected directly into a depleted IPFP, could improve the quality, density, and cellularity of the fat pad, and through paracrine effects, reduce knee inflammation and pain, in patients with symptomatic knee OA. The goal of our study was to test this hypothesis and document changes with ultrasound. The following is a summary of our methods and results.

### Case Series: Using Stem Cell-Rich Prolotherapy to Improve Knee Osteoarthritis

#### Materials and Methods

Several hundred knees have been treated with t-SVF/PRP over the past 10 years at our clinics (Hemwall Center for Orthopedic

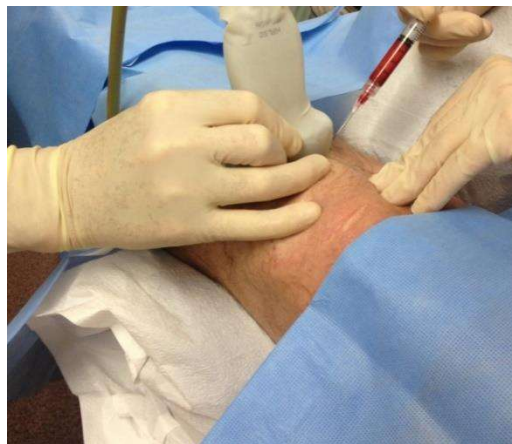Regenerative Medicine, Valencia and Alameda, California). Adipose extraction was done using the Tulip Medical cell-friendly microcannula system, following the Alderman-Alexander protocol<sup>40</sup> (see Figure)



Sterile adipose extraction

After centrifugation

Terumo-Harvest high-density PRP was prepared per standard protocol. Using ultrasound guidance, an average of 2 cc of t-SVF/PRP was directly injected into the IPFP (see Figure).



Other areas were also injected as per individual patient treatment plan. Ultrasound equipment was the Sonosite M-Turbo and the Konica Minolta Sonimage HS1. Post-procedure, patients were seen for follow-up twice, first at 4 to 6 months, then again at 9 to 12 months, when possible. Improvement was measured with repeat ultrasounds, direct exams, and a subjective questionnaire.

## General Results

Fifty-one patient charts were randomly selected for analysis. Patients were from 38 to 78 years old, with at least one prior unsuccessful, traditional intervention (corticosteroid, hyaluronic acid, NSAID, PT, and/or surgery). Analysis of Biocellular (Stem Cell-Rich) procedure results revealed no complications reported for any patient, either from adipose extraction or knee injections. Forty-seven of the 51 (92.1%) patients reported subjective improvement in pain and function at an average of 158-day follow-up. Three patient charts were examined in detail. The three patients chosen for elaboration represent varying age groups and presented with different symptoms and severity. The associated figures show

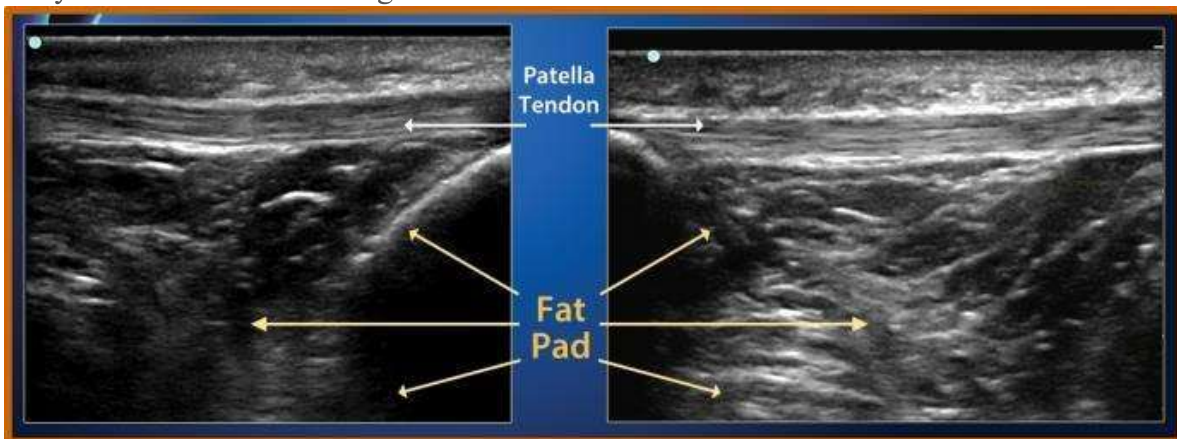
ultrasound imaging of the IPFP before, and after, t-SVF/PRP.

## Case Examples

### Patient Example #1

A 72-year-old male, presenting with moderately severe OA and a 3-year history of right knee pain, crepitus, and instability

Before treatment, ultrasound imaging showed extensive hypoechoic regions of the IPFP and a tendonotic patella tendon. Six months after treatment, imaging revealed increased tissue density of both the IPFP and patella tendon (see Figure 3). The patient reported overall decreased pain and increased stability, with a huge improvement in functionality and quality of life (QOL).



Patient 1 before (left) and after treatment

### Patient Example #2

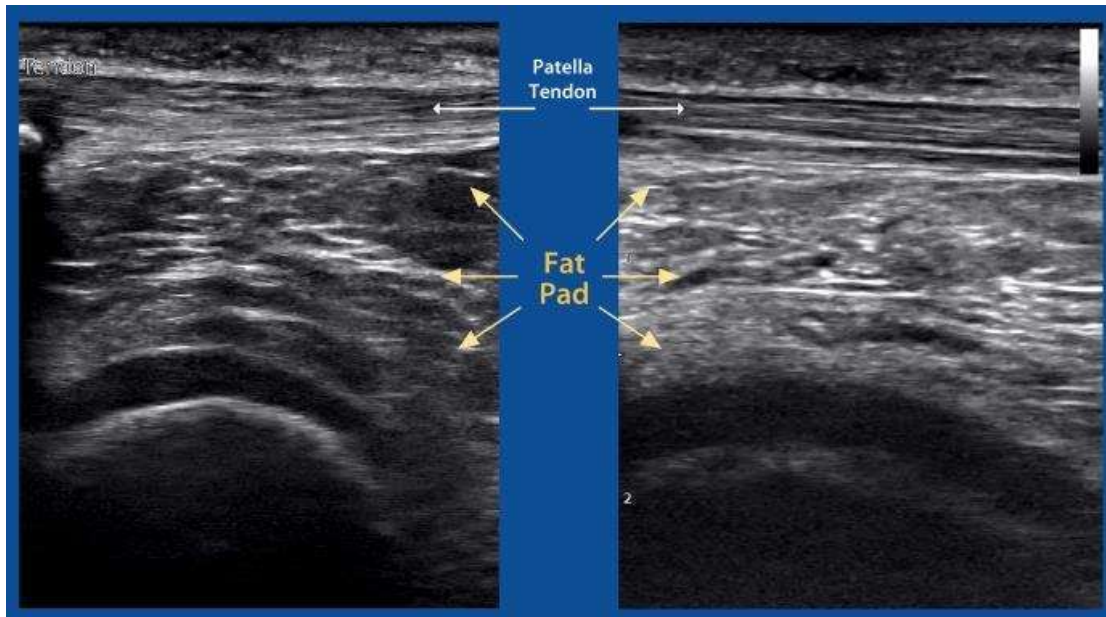
A 52-year-old female, presenting with moderately severe chondromalacia, mild-to-moderate cartilage degeneration, left knee pain, tracking dysfunction, and a “plucking sensation” with movement.

Pain/discomfort level prior to treatment was rated by the patient as severe, with moderate reduction of activity. Ultrasound imaging showed hypoechoic regions, disorganized tissue fibers, and degenerative changes in

the IPFP. Nine months after treatment, imaging revealed improved density of previously hypoechoic regions, better organization of tissue fibers, and improved joint space see Figure 4).

The patient reported a huge reduction of symptoms, elimination of the “plucking sensation,” and improvement in overall pain, leading to increased activity and functionality.





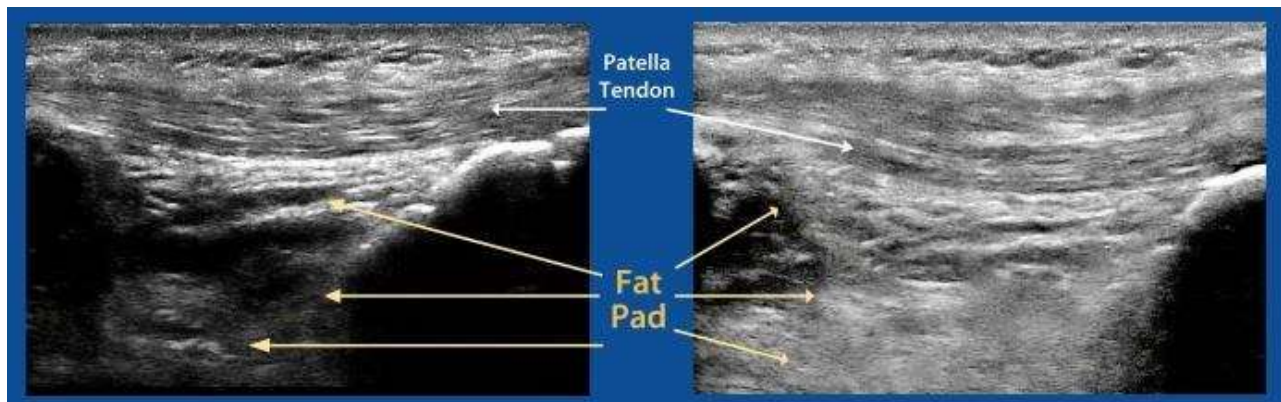
Patient 2 before (left) and after treatment

**Patient Example #3**

A 38-year-old male, presenting with a history of right ACL reconstruction surgery 10 years prior.

This patient reported reduced activity because of pain over the past 2 years, and a constant sensation of instability. Imaging

indicated a large region of low tissue density of the IPFP, a tendonotic patellar tendon, and moderate degenerative joint changes. Nine months after treatment, imaging revealed significant improvement of both the IPFP and patellar tendon (see Figure 5). The patient reported a drastic improvement in pain, stability, functionality, and QOL.



Patient 3 before (left) and after treatment

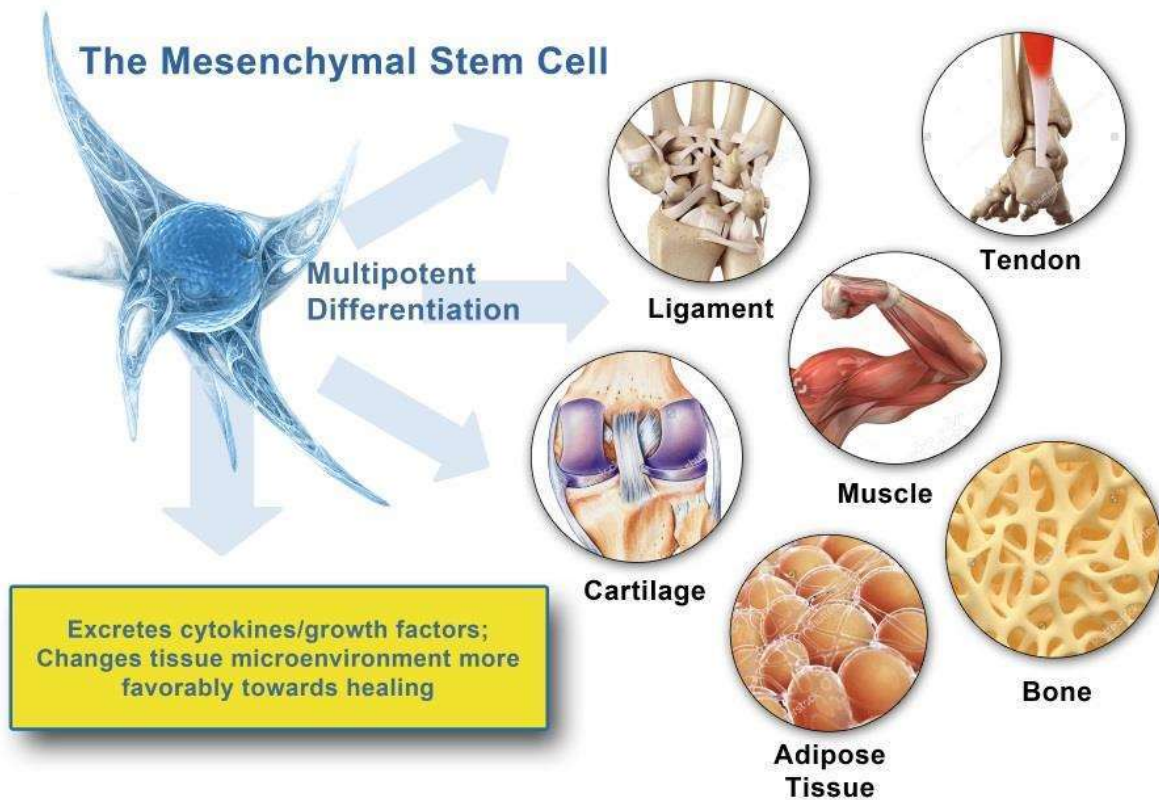
**Discussion**

Twenty years ago, researchers discovered adipose as an important mesenchymal stem

cell source.<sup>41</sup> Adipose contains hundreds of times more MSCs than bone marrow and is

more easily obtained with a minimally invasive procedure. Adipose-derived MSCs can also commit toward the chondrogenic, osteogenic, adipogenic, myogenic, and neurogenic lineages<sup>42,43</sup> (see Figure below). Furthermore, adipose retains its regenerative ability longer than bone marrow does,

making it an ideal stem cell source for older adults.<sup>44-46</sup> Our protocol uses autologous adipose, together with PRP, because this combination has been found to be synergistic, providing enhanced healing in multiple studies.<sup>47-49</sup>



The function of the infrapatellar fat pad is often debated. However, it is generally believed to be two-fold:

1. to provide padding, lubrication,<sup>50</sup> and shock absorption for the knee joint<sup>51</sup>
2. as a source of adult MSCs, for use in connective tissue, cartilage, and joint repair.<sup>52,53</sup>

In fact, regarding point #2, it is believed that a healthy fat pad may provide a protective role in knee OA.<sup>54</sup> Conversely, an unhealthy fat pad may represent reduction of the MSC

population and may contribute to degenerative changes through excretion of inflammatory proteins.<sup>55</sup> Since there is also depletion and/or functional alteration of MSC populations associated with osteoarthritis,<sup>56</sup> supplying healthy adipose, with its high population of MSCs, together with PRP growth factors, directly into a depleted IPFP, theoretically has the potential to restore the IPFP to health and replenish MSC supply. A secondary effect of t-SVF/PRP treatment could be MSC paracrine signaling to promote cartilage and connective

tissue repair and shift the microenvironment more favorably toward healing.<sup>57</sup>

In 2017, Adriani et al hypothesized that subcutaneous adipose, with its high content of MSCs, injected into the knee [joint](#) might contribute to cartilage healing and improve mechanical joint function in patients with OA. The Adriani study had positive results and concluded that autologous fat transfer into the joint is a viable treatment for knee

OA symptoms.<sup>58</sup> However that study lacked ultrasound imaging for guidance, or to evaluate changes. Adriani also did not inject directly into the IPFP, or consider its relationship or importance, and did not use PRP. Our study expanded upon Adriani by including ultrasound guidance and pre/post imaging, direct injections into the IPFP, and incorporation of PRP into the treatment protocol.

## Conclusion

In reviewing cases over a 10-year-period, we have found that adipose-derived biocellular (stem cell-rich) prolotherapy, injected directly into the infrapatellar fat pad, correlates with improvement in quality and density of the fat pad, knee pain reduction, and increased function in patients with moderate-to-severe knee OA. The mechanism of this treatment is likely by:

- providing additional structure and cushioning in the knee
- reducing inflammation
- replenishing fat pad Mesenchymal Stem Cells (MSCS) for current or future joint repair.

MSCs also have paracrine effects that encourage the microenvironment toward healing, and the capability of multipotent differentiation, making cartilage and/or connective tissue repair possible. Biocellular prolotherapy is an appropriate treatment for knee osteoarthritis, especially when traditional treatment, or PRP alone, has failed or results have leveled off. Further study is warranted.

---

1. Tiulpin A, Klein S, Bierma-Zeinstra SMA, Thevenot J, et al. Multimodal Machine Learning-based Knee Osteoarthritis Progression Prediction from Plain Radiographs and Clinical Data. *Sci Rep.* 2019; 9(1):1-11.

2. Georgiev T, Angelov AK. Modifiable risk factors in knee osteoarthritis: treatment implications. *Rheumatol Int.* 2019 Jul;39(7):1145-1157.

3. National Center for Health Statistics. Life expectancy. May 3, 2017. Available at: [www.cdc.gov/nchs/fastats/life-expectancy.htm](http://www.cdc.gov/nchs/fastats/life-expectancy.htm) Accessed: September 1, 2020.

4. Murphy SL, Xu J, Kochanek KD, Arias E. Mortality in the United States, 2017. *NCHS Data Brief.* 2018 Nov;(328):1-8.

5. World population gains more than a decade's life expectancy since 1970. December 13, 2012. Available at: <https://medicalxpress.com/news/2012-12-world-population-gains-decade-life.html>. Accessed: September 17, 2020.

6. Deshpande BR, Katz JN, Solomon DH, Yelin EH, et al. Number of persons with symptomatic knee osteoarthritis in the US: impact of race and ethnicity, age, sex, and obesity. *Arthritis Care Res.* 2016 Dec;68(12):1743-50.

7. Martin CL, Browne JA. Intra-articular Corticosteroid Injections for Symptomatic Knee Osteoarthritis: What the Orthopaedic Provider Needs to Know. *J Am Acad Orthopaedic Surg.* 2019(27):17; e758-e766.

8. Maniar KH, Jones IA, Gopalakrishna R, Vangsness CT Jr. Lowering side effects of NSAID usage in osteoarthritis: recent attempts at minimizing dosage. *Expert Opin Pharmacother.* 2018 Feb;19(2):93-102.

9. Zeng C, Lane NE, Hunter DJ, et al. Intra-articular corticosteroids and the risk of knee osteoarthritis progression: results from the osteoarthritis initiative. *Osteoarthr Cartil.* 2019 Jun 1;27(6):855-862.

10. Wijn SR, Rovers MM, van Tienen TG, Hannink G. Intra-articular corticosteroid injections increase the risk of requiring knee arthroplasty: a multicentre longitudinal observational study using data from the Osteoarthritis Initiative. *Bone Joint J.* 2020 May;102(5):586-592.
11. Waltychev M, Mattie R, McCormick Z, Laimi K. The Magnitude and Duration of the Effect of Intra-articular Corticosteroid Injections on Pain Severity in Knee Osteoarthritis: A Systematic Review and Meta-Analysis. *Am J Phys Med Rehabil.* 2020 Jul;99(7):617-625.
12. Altman R, Hackel J, Niazi F, Shaw P, Nicholls M. Efficacy and safety of repeated courses of hyaluronic acid injections for knee osteoarthritis: A systematic review. *Semin Arthritis Rheum.* 2018 Oct;48(2):168-175.
13. Rutjes AW, Jüni P, da Costa BR, et al. Viscosupplementation for osteoarthritis of the knee: a systematic review and meta-analysis. *Ann Int Med.* 2012 Aug 7;157(3):180-191.
14. Moseley JB, O'Malley K, Petersen NJ, et al. A controlled trial of arthroscopic surgery for osteoarthritis of the knee. *New Eng J Med.* 2002 Jul 11;347(2):81-88.
15. Sonesson S, Kvist J, Yakob J, Hedevik H, Gauffin H. Knee Arthroscopic Surgery in Middle-Aged Patients With Meniscal Symptoms: A 5-Year Follow-up of a Prospective, Randomized Study. *Orthop J Sports Med.* 2020;8(1):2325967119893920.
16. McGrory B, Weber K, Lynott JA, et al. The American Academy of Orthopaedic Surgeons evidence-based clinical practice guideline on surgical management of osteoarthritis of the knee. *J Bone Joint Surg.* 2016 Apr 20;98(8):688-692.
17. Raeissadat SA, Rayegani SM, Hassanabadi H, Fathi M, Ghorbani E, Babaee M, Azma K. Knee Osteoarthritis Injection Choices: Platelet-Rich Plasma (PRP) Versus Hyaluronic Acid (A one-year randomized clinical trial). *Clin Med Insights Arthritis Musculoskelet Disord.* 2015 Jan 7;8:1-8.
18. Migliorini F, Driessen A, Quack V, Sippel N, Cooper B, Mansy YE, Tingart M, Eschweiler J. Comparison between intra-articular infiltrations of placebo, steroids, hyaluronic and PRP for knee osteoarthritis: a Bayesian network meta-analysis. *Arch Orthop Trauma Surg.* 2020 Jul 28.
19. Cook CS, Smith PA. Clinical update: why PRP should be your first choice for injection therapy in treating osteoarthritis of the knee. *Curr Rev Musculoskelet Med.* 2018 Dec 1;11(4):583-592.
20. Jang SJ, Kim JD, Cha SS. Platelet-rich plasma (PRP) injections as an effective treatment for early osteoarthritis. *Eur J Orthop Surg Traumatol.* 2013 Jul;23(5):573-80.
21. Görmeli G, Görmeli CA, Ataoglu B, Çolak C, Aslantürk O, Ertem K. Multiple PRP injections are more effective than single injections and hyaluronic acid in knees with early osteoarthritis: a randomized, double-blind, placebo-controlled trial. *Knee Surg Sports Traumatol Arthrosc.* 2017 Mar;25(3):958-965.
22. Yancheng S, Junhui Z, Hualiang X, et al. Mesenchymal stem cells in knee osteoarthritis treatment: A systematic review and meta-analysis. *Journal of Orthopaedic Translation.* 2020 Apr 27
23. Davatchi F, Abdollahi BS, Mohyeddin M, et al. Mesenchymal stem cell therapy for knee osteoarthritis. Preliminary report of four patients. *Int J Rheum Dis.* 2011 May;14(2):211-215.
24. Freitag J, Bates D, Boyd R, et al. Mesenchymal stem cell therapy in the treatment of osteoarthritis: reparative pathways, safety and efficacy—a review. *BMC Musculoskel Dis.* 2016; 17(1):230.
25. Murphy MB, Moncivais K, Caplan AI. Mesenchymal stem cells: environmentally responsive therapeutics for regenerative medicine. *Exp Mol Med.* 2013 Nov;45(11):e54.
26. IBID
27. Usuelli FG, Grassi M, Maccario C, et al. Intra-articular adipose-derived stromal vascular fraction (SVF) injection provides a safe, efficacious treatment for Achilles tendinopathy: results of a randomized controlled clinical trial at a 6-month follow-up. *Knee Surg Sports Traumatol Arthrosc.* 2018 Jul;26(7):2000-2010.
28. Zuk PA, Zhu M, Ashjian P, et al. Human adipose tissue is a source of multipotent stem cells. *Mol Biol Cell.* 2002;13(12):4279-4295.
29. Fraser JK, Wulur I, Alfonso Z, Hedrick MH. Fat tissue: an underappreciated source of stem cells for biotechnology. *Trends Biotechnol.* 2006;24(4):150-154.
30. Kern S, Eichler H, Stoeve J, et al. Comparative analysis of mesenchymal stem cells from bone marrow, umbilical cord blood, or adipose tissue. *Stem Cells.* 2006 May;24(5):1294-1301.
31. Tangchitphisit P, Srikaew N, Numhom S, et al. Infrapatellar Fat Pad: An Alternative Source of Adipose-Derived Mesenchymal Stem Cells. *Arthritis.* 2016;2016:4019873.
32. Han W, Aitken D, Zhu Z, et al. Hypointense signals in the infrapatellar fat pad assessed by magnetic resonance imaging are associated with knee symptoms and structure in older adults: a cohort study. *Arthritis Res Ther.* 2016 Oct 12;18(1):234.
33. Clockaerts S, Bastiaansen-Jenniskens YM, Runhaar J, et al. The infrapatellar fat pad should be considered as an active osteoarthritic joint tissue: a narrative review. *Osteoarthr Cartilage.* 2010 Jul 1;18(7):876-882.
34. Ruhdorfer A, Haniel F, Petersohn T, et al. Between-group differences in infra-patellar fat pad size and signal in symptomatic and radiographic progression of knee osteoarthritis vs non-progressive controls and healthy knees—data from the FNIH Biomarkers Consortium Study and the Osteoarthritis Initiative. *Osteoarthr Cartilage.* 2017 Jul 1;25(7):1114-21.
35. Eymard F, Pigenet A, Citadelle D, et al. Induction of an inflammatory and prodegradative phenotype in autologous

- fibroblast-like synoviocytes by the infrapatellar fat pad from patients with knee osteoarthritis. *Arthr Rheumatol*. 2014 Aug;66(8):2165-2174.
36. Zeng N, Yan ZP, Chen XY, Ni GX. Infrapatellar Fat Pad and Knee Osteoarthritis. *Aging Dis*. 2020 Oct.
37. Shimozone Y, Fortier LA, Brown D, Kennedy JG. Adipose-based therapies for knee pain—fat or fiction. *J Knee Surg*. 2019 Jan;32(01):055-64.
38. Freitag J, Bates D, Wickham J, et al. Adipose-derived mesenchymal stem cell therapy in the treatment of knee osteoarthritis: a randomized controlled trial. *Regen Med*. 2019 Mar;14(3):213-30.
39. Miana VV, González EAP. Adipose tissue stem cells in regenerative medicine. *Ecancermedicalscience*. 2018 Mar 28;12:822.
40. Alderman D, Alexander, RW, Harris, GR, Astourian, PC. Stem Cell Prolotherapy in Regenerative Medicine: Background, Theory and Protocols. *J Prolother*. 2011 Aug;3(3):689-702.
41. Zuk PA, Zhu MI, Mizuno H, et al. Multilineage cells from human adipose tissue: implications for cell-based therapies. *Tissue Engineer*. 2001 Apr 1;7(2):211-28.
42. Izadpanah R, Trygg C, Patel B, et al. Biologic properties of mesenchymal stem cells derived from bone marrow and adipose tissue. *J Cell Biochem*. 2006 Dec 1;99(5):1285-1297.
43. Zuk, Patricia A. The adipose-derived stem cell: looking back and looking ahead. *Mol Biol Cell*. 2010 (21)11:1783-1787.
44. Dufrane D. Impact of Age on Human Adipose Stem Cells for Bone Tissue Engineering. *Cell Transplant*. 2017 Sep;26(9):1496-1504.
45. Fraser JK, Wulur I, Alfonso Z, Hedrick MH. Fat tissue: an underappreciated source of stem cells for biotechnology. *Trends Biotechnol*. 2006 Apr;24(4):150-4.
46. Buschmann J, Gao S, Härter L, Hemmi S, 15et al. Yield and proliferation rate of adipose-derived stromal cells as a function of age, body mass index and harvest site-increasing the yield by use of adherent and supernatant fractions? *Cytherapy*. 2013 Sep;15(9):1098-1105.
47. Blanton MW, Hadad I, Johnstone BH, et al. Adipose stromal cells and platelet-rich plasma therapies synergistically increase revascularization during wound healing. *Plastic Reconstruct Surg*. 2009 Feb 1;123(2S):56S-64S.
48. Modarressi A. Platelet Rich Plasma (PRP) Improves Fat Grafting Outcomes. *World J Plastic Surg*. 2013;2(1):6-13.
49. Tobita M, Tajima S, Mizuno H. Adipose tissue-derived mesenchymal stem cells and platelet-rich plasma: stem cell transplantation methods that enhance stemness. *Stem Cell ResTher*. 2015 Nov (5)6:215.
50. Davies DV, White JE. The structure and weight of synovial fat pads. *J Anat*. 1961 Jan;95(Pt 1):30.
51. Han W, Cai S, Liu Z. Infrapatellar fat pad in the knee: is local fat good or bad for knee osteoarthritis? *Arthr ResTher*. 2014 Jul 9;16(4):R145.
52. Muñoz-Criado I, Meseguer-Ripolles J, Mellado-López M, et al. Human Suprapatellar Fat Pad-Derived Mesenchymal Stem Cells Induce Chondrogenesis and Cartilage Repair in a Model of Severe Osteoarthritis. *Stem Cells International*. Epub 2017 Jul 9.
53. Tangchitphisut P, Srikaew N, Numhom S, et al. Infrapatellar Fat Pad: An Alternative Source of Adipose-Derived Mesenchymal Stem Cells. *Arthritis*. Epub 2016 Apr 26.
54. IBID 51
55. Eymard F, Pigenet A, Citadelle D, et al. Induction of an inflammatory and prodegradative phenotype in autologous fibroblast-like synoviocytes by the infrapatellar fat pad from patients with knee osteoarthritis. *Arthr Rheumatol*. 2014 Aug;66(8):2165-2174.
56. Luyten FP. Mesenchymal stem cells in osteoarthritis. *Curr Op Rheumatol*. 2004 Sep 1;16(5):599-603.
57. Barry F, Murphy M. Mesenchymal stem cells in joint disease and repair. *Nature Rev Rheumatol*. 2013 Oct;9(10):584-594.
58. Adriani E, Moio M, Di Paola B, et al. Percutaneous fat transfer to treat knee osteoarthritis symptoms: preliminary results. *Joints*. 2017 Jun;5(2):89-92.